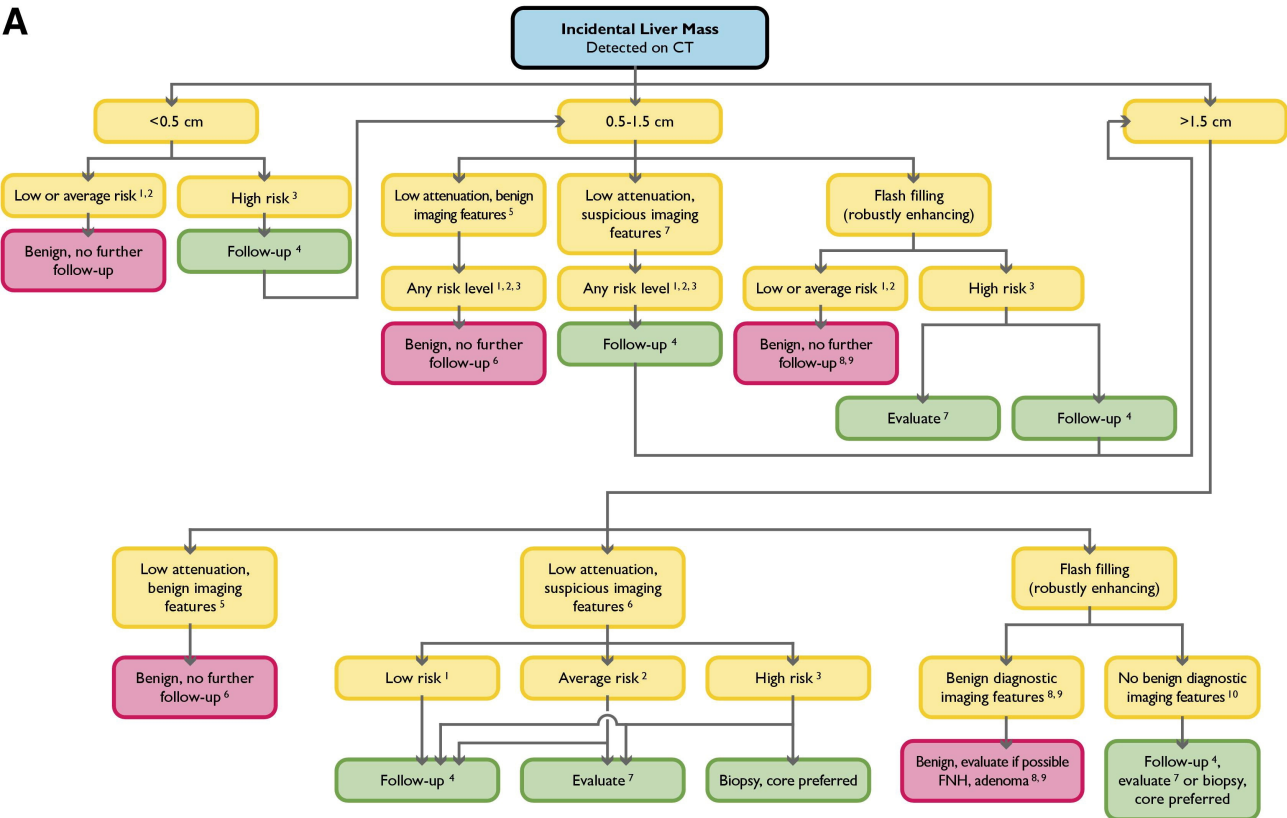



A



B



LEGEND

- Low risk individuals: Young patient (≤ 40 years old), with no known malignancy, hepatic dysfunction, hepatic malignant risk factors, or symptoms attributable to the liver.
- Average risk individuals: Patient >40 years old, with no known malignancy, hepatic dysfunction, abnormal liver function tests or hepatic malignant risk factors or symptoms attributable to the liver.
- High risk individuals: Known primary malignancy with a propensity to metastasize to the liver, cirrhosis, and/or other hepatic risk factors. Hepatic risk factors include hepatitis, chronic active hepatitis, sclerosing cholangitis, primary biliary cirrhosis, hemochromatosis, hemosiderosis, oral contraceptive use, anabolic steroid use.
- Follow-up CT or MRI in 6 months. May need more frequent follow-up in some situations, such as a cirrhotic patient who is a liver transplant candidate.
- Benign imaging features: Typical hemangioma (see below), sharply marginated, homogeneous low attenuation (up to about 20 HU), no enhancement. May have sharp, but irregular margins.
- Benign low attenuation masses: Cyst, hemangioma, hamartoma, Von Meyenberg complex (bile duct hamartomas).
- Suspicious imaging features: Ill-defined margins, enhancement (more than about 20 HU), heterogeneous, enlargement. To evaluate, prefer multiphase MRI.
- Hemangioma features: Nodular discontinuous peripheral enhancement with progressive enlargement of enhancing foci on subsequent phases. Nodule isodense with vessels, not parenchyma.
- Small robustly enhancing lesion in average risk, young patient: hemangioma, focal nodular hyperplasia (FNH), transient hepatic attenuation difference (THAD) flow artifact, and in average risk, older patient: hemangioma, THAD flow artifact. Other possible diagnoses: adenoma, arterio-venous malformation (AVM), nodular regenerative hyperplasia. Differentiation of FNH from adenoma important especially if larger than 4 cm and subcapsular.
- Hepatocellular or common metastatic enhancing malignancy: islet cell, neuroendocrine, carcinoid, renal cell carcinoma, melanoma, choriocarcinoma, sarcoma, breast, some pancreatic lesions.